Localization of tumor necrosis factor in the canine testis, epididymis and spermatozoa

R Payan-Carreira, I Santana, M A Pires, B Strom Holst and Heriberto Rodriguez-Martinez

Linköping University Post Print

N.B.: When citing this work, cite the original article.

Original Publication:

R Payan-Carreira, I Santana, M A Pires, B Strom Holst and Heriberto Rodriguez-Martinez, Localization of tumor necrosis factor in the canine testis, epididymis and spermatozoa, 2012, Theriogenology, (77), 8, 1540-1548.
http://dx.doi.org/10.1016/j.theriogenology.2011.11.021
Copyright: Elsevier
http://www.elsevier.com/

Postprint available at: Linköping University Electronic Press
http://urn.kb.se/resolve?urn=urn:nbn:se:liu:diva-77323

Revised

LOCALIZATION OF TUMOUR NECROSIS FACTOR IN THE CANINE TESTIS, EPIDIDYMIS AND SPERMATOZOA

R Payan-Carreira[a]*, Santana, I [a], M A Pires[a], B. Ström Holst[b], H. Rodriguez-Martinez[c]

[a] CECAV, University of Trás-os-Montes and Alto Douro, P.O. Box 1013, 5001-801 Vila Real, Portugal.

[b] SLU, Dept. of Clinical Sciences, Box 7054, 750 07 Uppsala, Sweden

[c] Dept of Clinical & Experimental Medicine, University of Linköping, 58185, Linköping Sweden

Running head: TNF in dog testis, epididymis and sperm cell

* Corresponding author: Rita Payan-Carreira, CECAV, Department of Zootecnics, University of Trás-os-Montes and Alto Douro; Vila Real, Portugal; Fax: +351.259350482. E-mail address: rtpayan@gmail.com

Abstract

Tumour necrosis factor (TNF), formerly known as Tumour necrosis factor alpha is now regarded as a natural component of the mammalian seminal plasma (SP). Although not completely clarified, its functions in the SP have been associated with paradoxal roles, such as sperm survival in the female genital tract, while at high levels negatively affect sperm survival and fertility potential. Recently, it has been discovered that canine inseminated spermatozoa display a strong immunoreaction for TNF when lining the female endometrium. As a continuation of this finding, the present work aimed at documenting TNF localization in the canine testes and epididymis and in freshly ejaculated spermatozoa (SPZ) through immunohisto- or cytochemistry. Immunoreaction for TNF was found in all samples used. In the dog testis, TNF immunoexpression was limited to the seminiferous tubules, where late round spermatids (SPD) showed weak intensity of immunostaining, whilst elongating and elongated SPD evidenced moderate and the residual bodies a strong intensity. In the epididymis, a gradual progressive increase of TNF immunolabelling was found throughout the epididymal regions, ranging from a weak intensity at the caput epididymis to a moderate intensity at the cauda. TNF immunolabelling was found in mature SPZ during the epididymal transit and also in freshly ejaculated SPZ, which showed a strong mid-piece immunolabelling. Data presented here provide important information on expression of TNF in spermatozoa, which is acquired by the SPZ during their formation at the testis. It further provides the basis for subsequent studies on the physiological importance of cytokines in sperm function.

Key words: Tumour necrosis factor-alpha; Spermatogenesis; Testis; Spermatozoa; Dog.

Introduction

Tumour necrosis factor (TNF), formerly named Tumour Necrosis Factor alpha, is a cytokine with a wide spectrum of effects, including pro-inflammatory and immunoregulatory activities, stimulation of cell growth and differentiation and promotion of cell survival and apoptosis, in a dose-dependent way [1].

TNF, among other cytokines, is now considered a natural component of the seminal plasma (SP), although its physiological significance in sperm function is not fully clarified [2]. TNF was found to be present in small amounts in human [3,4], bull [5] and pig semen [6] and it has also been demonstrated to be present in both the male and female reproductive tract from normal individuals [7,8]. Its presence has been associated with the regulation of several physiological functions in both the male and female genital tract, possibly including ovulation [9] and the fertilization process [2,8,10].

Increased levels of TNF have been found in semen from infertile men and have been associated with poor semen quality [11]. In addition, introduction of exogenous TNF to sperm samples has proven deleterious to the survival and fertility potential of spermatozoa [12]. It has been proposed that increased levels of TNF in seminal plasma could be associated with increased sperm membrane lipid peroxidation [13] and a reduction of sperm motility [11,14], with inhibition of the acrosome reaction [15] and impairment of sperm binding to the zona pellucida [16].

TNF protein has also been found in a large variety of structures within the male reproductive system, such as the testis and epididymis. In mouse testis, TNF transcripts were found in pachytene spermatocytes, round spermatids and in interstitial macrophages, although secretion of active TNF was only found in the spermatid fraction.

In addition, some TNF expression was found in residual bodies, but this was proposed to be due to the presence of spermatids [17].

Until now, TNF has been thought to be incorporated into the seminal plasma in the male genital tract, by epithelial cells at the epididymis or by secretion of the vesicular glands and the prostate [11]. However, references on the presence of this molecule in spermatozoa were not available until recently. We have discovered, by immunohistochemistry in histological sections, that canine spermatozoa display a strong positive immunolabelling for TNF when lining to the female endometrium, after mating [18]. As a continuation of these studies, we next sought to localize TNF in the canine fresh, ejaculated spermatozoa, and also on dog testes and epididymis, in an attempt to determine if sperm acquisition of TNF whether occurs during their formation (at testes level) or during their maturation (at the epididymis level).

2. Material and methods

Testicular and epididymal samples

Testicular and epididymal samples were obtained from five mature male dogs at orchiectomy. The dogs had been submitted for elective surgery for legal reasons (the Portuguese legislation obliges the neutering of male dogs from breeds considered to be potentially dangerous), and their age ranged from 18 months to 5 years-old.
Excised testes with adjacent epididymis were cut longitudinally, immersed in 10% buffered formalin immediately after surgery and routinely embedded in paraffin. Routine haematoxylin-eosin staining was used to evaluate the samples and exclude those with signs of inflammation or neoplasia. From each testis, a longitudinal section of the gonad was used for immunohistochemical detection of TNF expression. The epididymides were separated from the testes, and longitudinally cut. From each epididymal hemisection,

transversal sections at the level of the caput, corpus and cauda were obtained (Figure 1A), in a segment-specific manner [19], and employed for immunohistochemistry.

Semen samples

Fresh ejaculates were obtained by digital manipulation from 5 dogs of different breeds. Only the second fraction of the ejaculate (the sperm rich fraction) was collected, as for cryopreservation. The animals were clinically healthy, and were previously proven to be fertile or routinely used for semen collection.

Sperm smears were made from each ejaculate in Poly-L-Lysine coated slides. As samples were too concentrated to allow proper evaluation, they were first diluted on the slide. The extender was chosen after comparison of undiluted to Dulbecco´s PBS (Phosphate buffered saline) and BTS (Beltsville Thawing Solution; IMV Technologies) diluted samples. In a first run, two samples from different dogs were prepared as described below and used to test the procedure. BTS was chosen for sperm extension instead of PBS because the later induced background crystal formation. Immunostaining was compared between BTS extended and non-extended samples and no differences were observed that could be attributed to BTS. Dilution was obtained during cytology preparation by extending 1:1 v/v of semen in BTS in the slide, and allowing it to air-dry before fixation for five minutes in 95% ethanol.

Immunohistochemistry (IHC) and immunocytochemistry (ICC)

IHC analysis was performed using a streptavidin-biotin-peroxidase complex method and a polymeric labelling methodology as a detection system (Novolink Polymer Detection System, Novocastra), according to the manufacturer’s instructions, on 3-µm-thick tissue sections prepared from formalin-fixed, paraffin-embedded archival tissue. The sections were submitted to routine deparaffinization and rehydration in graded alcohol, followed by

antigen retrieval in a steamer for 2 min, with slides immersed in citrate buffer (pH = 6). For quenching endogenous peroxidases, the sections were immersed in 3% hydrogen peroxide for 30 min. Non-specific binding of the primary antibody was blocked by incubation with a polyvalent blocking serum (Ultra V Block®, Thermo Fisher Scientific, LabVision Corporation, Fremont, CA, USA), followed by incubation with a specific monoclonal primary antibody raised against full length recombinant canine TNF molecule (sc-80386; Santa Cruz Biotechnology, Inc., Europe, Heidelberg, Germany), at a 1:50 dilution in PBS. After an overnight incubation with the primary antibody, at 4ºC, in a humid chamber, tissue sections were incubated with Biotinylated Goat Polyvalent Plus® antibody (Thermo Fisher Scientific, LabVision Corporation, Fremont, CA, USA), followed by incubation with Streptavidin-peroxidase Plus® (Thermo Fisher Scientific, LabVision Corporation, Fremont, CA, USA). The 3,3´diaminobenzidine (DAB) was used as chromogen. The sections were then counterstained with Gill´s haematoxylin, dehydrated and mounted for evaluation by light microscopy. Samples of canine ovaries with mature corpora lutea were submitted to the same procedure and used as positive control (Figure 1B) [18]. Testicular vessels included in tissue sections were also utilized as internal positive controls. Testes samples incubated with mouse IgG (sc-2025; Santa Cruz Biotechnology, Inc., Europe, Heidelberg, Germany) and with PBS were used as negative controls. TNF-immunoreactivity was not observed in any negative control.

In the cytological specimens, the immunocytochemistry (ICC) was performed according to the same protocol as the one used for the histological samples, including the incubation time with the primary antibody, with exception to the steps consisting in immersion in Xylene for deparaffinization and passages by 100% and 95% ethanol. The same procedure was carried out for the negative controls, where the primary antibody was replaced with mouse IgG (sc-2025; Santa Cruz Biotechnology, Inc., Europe, Heidelberg, Germany) and with PBS. TNF-immunoreactivity was not observed in any negative control.

Immunostain scoring

Positive cytoplasmic staining for TNF was scored estimating staining intensity (0: no staining; 1: weak; 2: moderate; 3: strong) of immunoreactive cells, operator-wise. Positivity was indicated by the presence of a distinct brownish to gold-colour labelling. The distribution of TNF immunoexpression within the testicular parenchyma and in the epididymis was evaluated independently for Leydig cells, Sertoli cells, spermatogenic epithelium, epididymal epithelium and the spermatozoa. Immunolabeling scores for germ cells were determined independently for each stage of the spermatogenic cycle, according to the arrangement of spermatogonia (SPG), spermatocytes (SPC), and spermatids (SPD) in the cross-sections of the seminiferous tubules. Dog spermatogenic staging was based on the classification proposed by Russel et al. [20]; one additional stage, named stage V.b, was introduced corresponding to end of stage V, where residual bodies were still observed in the seminiferous tubules, along with young round spermatids, but step 12 SPD were no longer observed on tubular cross-sections.

In the epididymis, TNF immunoreaction was scored for the epididymal epithelium and also for sperm cells within the epididymal duct. Each epididymal segment (caput, corpus and cauda) was evaluated independently, with the corpus of epididymis further sub-divided in upper (proximal or part 1) and lower (caudal or part 2) areas (Figure 1A) [19]. Inside the epididymal duct, the sperm cells closer to the epithelium, which were less crowded, were used for scoring.

Histological specimens were evaluated at 400x magnification. For each testicular sample, 10 different fields were assessed at 400x magnification, in order to evaluate at least 3 tubules depicting each stage of the canine spermatogenic cycle. Additionally, 4 fields in

each of the above-mentioned areas of the epididymis were evaluated. In the cytological preparations, 10 different fields were evaluated at 1000x magnification.

The immunostaining was independently scored by two observers; results from both observers presented a good repeatability in all the 3-point scale used for scoring the TNF immunostaining.

Statistical analysis

Statistical comparisons were performed by using the IBM SPSS Statistics Base 17.0 statistical software for Windows®.

Associations between the intensity of immunoexpression for TNF and the variables stage of the spermatogenic cycle and cell type and segments of epididymis were performed using the chi-square and Fisher exact tests. A P value ≤ 0.05 was regarded as statistically significant.

3. Results

TNF immunoexpression in canine testes and epididymis

Immunohistochemical staining indicating that TNF was present in the dog testis, epididymis and spermatozoa was found in all samples studied. Strong to moderate intensity of immunolabelling was found in mature canine corpora lutea, which were used as positive control for the IHC (Figure 1B). The use of PBS or of the mouse IgG as a substitute for the primary antibody, in the ICC, as well as in IHC, resulted in the absence of positive immunolabelling in both tissue sections and cytology specimens.

In dog testes, positive immunolabelling for TNF was observed inside the seminiferous tubules, in particular in germ cells, and in the interstitium. A weak TNF positive immunolabelling was sporadically observed in interstitial macrophages, whereas in all the

studied samples Sertoli cells, Leydig cells and myoid peritubular cells were negative for TNF (Figure 2). The intensity of TNF immunoreactions within the seminiferous tubules was detected at all the stages of the spermatogenesis and was statistically associated with the spermatogenic cycle (P<0.001; Fisher = 106.675). Moreover, it was found that different germ cell types consistently presented the same TNF immunoexpression (P<0.001; Fisher = 415.234). Independently of the cycle stage, spermatogonia (SPG) and spermatocytes (SPC) did not present immunoreaction against this protein (Figure 2). Positive immunolabelling was only observed in spermatids and step12 SPD (Figure 2), which consistently showed different immunolabeling intensities according to the stage of the spermatogenic cycle (P<0.001; Fisher = 120.222). Overall, the intensity of TNF immunoexpression was lower in early round spermatids (Figure 2A) when compared to the elongated spermatids (Table 1; Figures 2B to 2D). In addition, strong immunolabeling for this molecule was also observed in residual bodies, in stage V, which remained attached to the cytoplasm of Sertoli cells (Table 1; Figure 2D).

Each epididymal segment (caput, corpus 1 and 2, and cauda) was also scored for TNF immunoreactivity (Figure 3A to 3D). A slight gradual increase in the intensity score was found from the proximal epididymal regions to the more distal ones (Table 2). The epithelium of the epididymal duct at the caput (Figure 3A) and cranial corpus region (Figure 3B) evidenced a weak intensity of immunostaining against TNF; intensity of immunostaining increases from the upper region of the corpus of epididymis to the cauda (P<0.001; Fisher = 24,257) (Figure 3B to 3D). Similar TNF immunoreaction was observed in the different epithelial cell types that integrate the epididymal epithelium (basal cell, principal cells and apical cells), and therefore the intensity of immunolabelling registered was considered as unique. In the caput region, a membrane pattern of TNF immunoreaction predominated, whilst from the corpus towards the cauda of the epididymis, a diffuse cytoplasmic pattern of immunolabeling prevailed. Sporadically,

diffuse immunostaining of cell blebbing was also observed (Figure 3B and 3C). This was more frequently observed in the lower region of the corpus of epididymis and in cauda epididymis than in the more proximal regions, although no statistical significance was found.

Spermatozoa present in the epididymal lumen of the caput epididymis (Figure 3A) evidenced a moderate immunostaining that was observed as a diffuse brownish staining of the Spz tail. Reinforcement of the staining at the proximal droplet was observed in sperm cells in a longitudinal presentation. Their intensity of TNF immunoreaction slightly increased from the corpus to the cauda epididymis (Figure 3A to 3D), and the sub-cellular location in the mid-piece became more evident.

TNF immunoexpression in ejaculated spermatozoa

Immunocytochemistry demonstrated positive immunostaining for TNF in freshly ejaculated sperm cells. Strong specific labeling was observed in all spermatozoa in the 10 fields analysed (Figure 3E). TNF immunoreaction was confined to the mid-piece of spermatozoa, with the remainder of the flagellum, as well as the sperm head and the neck being negative to this molecule (Figure 3F). There was no specific staining in the negative controls.

4. Discussion

TNF is a multifunctional, pleiotropic pro-inflammatory cytokine that exerts beneficial functions in cell growth and proliferation and in tissue remodelling [1,21]. In our study, TNF immunoexpression was found in canine seminiferous tubules, in the epididymal epithelium and sperm cells within the epididymal duct, and in freshly ejaculated spermatozoa. Furthermore, it was clearly demonstrated that the spermatozoa acquire TNF immunoreactivity during their formation at testicular level, and that this reactivity is maintained during the transit through the epididymis, up to the ejaculate.

The presence of this molecule in the testis was already shown for different species [17,22,23,24]. In mice, using in situ hybridization (ISH), De and collaborators [17] demonstrated that TNF expression varies with the spermatogenic stage and that this protein is mainly produced by spermatids. In contrast, no mRNA or protein has been found in the Sertoli cells or in Leydig interstitial cells. Data presented in this article demonstrate that positive immunostaining in canine testis was limited to the seminiferous epithelium, in post-meiotic germinative cells, as stated earlier in other species [17,22,24]. Sertoli cells were negative to TNF, as well as the Leydig cells in the testicular interstitium. In contrast, Siu et al [25] reported TNF immunoreactivity in rat Sertoli cell cytoplasm surrounding elongated spermatids at stage VIII that disappear preceding spermiation. However, other authors associate this positivity to the residual germ cell cytoplasm or residual body [17], where it was also observed in the present work. In fact, it is now accepted that TNF is not constitutively expressed in normal somatic cells of the seminiferous tubules [23], with only the activated macrophages in the interstitium secreting this molecule during inflammatory or immune-mediated conditions.

In the study presented here, a weak intensity of immunolabeling was observed in late round spermatids in tubules from stage V.b, after spermiation occurred, and also in elongating and elongated spermatids in tubules from stages VI and VII. Detection of low TNF protein immunoexpression in round spermatids preceded polarization of the cell, in step 6 SPD at late stage Vb [20], and remained low until maximal elongation was achieved, at stage VII. From this developmental stage on, a moderate intensity of immunostaining was observed in elongated SPD, accompanying condensation of the nucleus, that proceed in spermatids from stage I to IV [20]. Terminal SPD in tubules from stage V showed a moderate intensity of immunolabelling, whilst adluminal cytoplasmic areas corresponding to the residual bodies, in tubules from stages V and V.b, presented stronger intensity of immunolabeling.

Data gathered in this study do not allow definition of the TNF effects in the seminiferous tubule physiology. Nevertheless, it is now recognised that this molecule may exert several different functions on the seminiferous epithelium acting in a paracrine way through Sertoli cells, and some of them might explain the need for TNF secretion by spermatids. Among the TNF-associated roles within the seminiferous tubules are: the transferrin production [26,27], with highest demands by elongating and elongated spermatids, and the lactate production, the preferential energy substrate by post-meiotic germ cells [23,28]. Further, TNF has been associated with down-regulation of the Fas ligand pathway that promotes germ-cell survival [22,24]. Studies in different species show that apoptosis in the normal testicle is more frequent in spermatogonia and spermatocytes than in spermatids [29,30]. In the present study only the spermatids showed TNF immunostaining. Furthermore, TNF is involved with restructuring of the tight junctions and of the only anchoring device between Sertoli cells and post-meiotic spermatids, an essential step during spermatogenesis and spermiation [31,32,33].

In this study, Immunoreaction for TNF was also observed in the epithelium of all the epididymal regions and in the sperm cells inside the epididymal duct. The intensity of immunolabelling in the epithelium gradually increased from a weak intensity of immunostaining in more cranial parts to moderate intensity in the more distal ones. In the epididymis, the presence of TNF has been reported in some inflammatory diseases and after vasectomy or castration [34,35]. It has been demonstrated that TNF is expressed in low levels in the rat epididymis before an inflammatory stimulus [35, 36], and in the bull epididymis before trauma [37]. Zhao et al [36] defend that epididymal epithelial cells may account for the epididymal innate defense mechanism by producing several pro-inflammatory cytokines and other immunoregulatory mediators, such as the TNF. Taken together, these data suggest that a minimal threshold could be maintained for TNF in the

epididymis in non-pathological conditions, thus supporting the IHC results reported herein, where a diffuse immunolabelling was recorded. In addition, presence of TNF among other cytokines in the seminal fluid of different species was attributed to its incorporation in the fluid by the genital ducts or as result of the secretion of male accessory glands [3,4,5,6]. Sporadically, immunostained cell blebbing was observed in epididymal epithelial cells, which is compatible with TNF transfer into the epididymal fluid and posterior incorporation in the seminal plasma, as previously suggested [11].

Spermatozoa evidence a moderate intensity of TNF immunoexpression when at the caput epididymis, similar to the one observed in late spermatids before spermiation. This suggests that the molecule is already fixed in the immature spermatozoa at spermiation. It was also observed that the intensity of the immunoreaction became slightly stronger from the corpus to the cauda epididymis. Further it was also clear that the staining is limited to the sperm mid-piece in the cauda of the epididymis. From this study it is not possible to determine whether this increase in intensity could be related to water lost by the spermatozoa, to acquisition of progressive motility capacity or to remodelling of the plasma membrane, or even if it may be associated to incorporation of TNF secreted into the epididymal fluid. Further studies are needed to strengthen this issue, as little is known about sperm maturation process in the epididymis in the dog.

The ejaculated sperm cells showed a strong immunoreaction for TNF, similar to the one detected at the distal parts of the epididymis, allowing to suspect that concerning TNF content, the cauda epididymis retains mainly storage functions. The present study further showed that the ejaculated canine spermatozoa displayed strong TNF immunoreaction, which was limited to the cell mid-piece. Although the existence of TNF among other cytokines was demonstrated in the seminal plasma of several species [3,4,5,6], limited information was found on the presence of this molecule inside the spermatozoa [18]. TNF has been associated to the regulation of the local immune system at the female genital tract [38], to a decrease in the motility of human spermatozoa in both spontaneous

[11,39,40] and experimental conditions [11,14], and with increased production of reactive oxygen species [13,15,41] that could lead to the inhibition of the acrosome reaction [15] or impaired gamete interaction at fertilization [16].

The study presented here was designed to demonstrate the presence of TNF in the canine testis, in immature epididymal sperm cells and in the ejaculated spermatozoa. It demonstrated that canine spermatozoa acquired TNF immunoreaction in late stages of the spermatogenic process and that the presence of this protein persists in the ejaculated cell, in a subcellular localization that is limited to the sperm mid-piece, near the mitochondrial sheet. This particular, subcellular localization for TNF protein is suggestive of a possible role in the sperm motility, without excluding the hypothesis that the presence of this protein favours sperm cell survival in the female reproductive tract, protecting the cell from apoptotic events and from damage by reactive oxygen substances. However, additional studies are needed to clarify putative functions concerning TNF expression by the sperm cell, in particular concerning the female tract deposition, in acrosome reaction and fertilization. The presence of this molecule in sperm cells raises new queries on its possible function in gamete physiology, as so far presence of TNF has been reported only in seminal plasma and associated to sperm survival in female genital tract and to gamete interaction.

5. Acknowledgements

The authors thank Mrs. Ligia Lourenço (UTAD) and Mrs. Annika Rikberg (SLU) for their technical expertise.

This work was sponsored in part by the Portuguese Science and Technology Foundation (FCT) under the Project PEst-OE/AGR/UI0772/2011. FCT also granted Rita Payan Carreira with a sabbatical fellowship (SFRH/BSAB/938/2009) and Inês Santana with an *Integration into Research* fellowship (BII/UNI/0772/AGR/2009)

Conflict of Interests

None of the authors of this paper has a financial or personal relationship with other people or organizations that could inappropriately influence or bias the content of the paper.

6. References

[1] Wang H, Czura CJ, Tracey KJ, Angus WT, Michael TL. Tumor necrosis factor, The Cytokine Handbook (Fourth Edition). London: Academic Press, 2003;837-860.

[2] Fraczek M, Sanocka D, Kamieniczna M, Kurpisz M. Proinflammatory cytokines as an intermediate factor enhancing lipid sperm membrane peroxidation in in vitro conditions. J Androl 2008;29: 85-92.

[3] Maegawa M, Kamada M, Irahara M, Yamamoto S, Yoshikawa S, Kasai Y, Ohmoto Y, Gima H, Thaler CJ, Aono T. A repertoire of cytokines in human seminal plasma. J Reprod Immunol 2002;54: 33-42.

[4] Politch JA, Tucker L, Bowman FP, Anderson DJ. Concentrations and significance of cytokines and other immunologic factors in semen of healthy fertile men. Hum Reprod 2007;22: 2928-2935.

[5] Vera O, Vásqucz LA, Muñoz MG. Semen quality and presence of cytokines in seminal fluid of bull ejaculates. Theriogenology 2003;60: 553-558.

[6] Turba ME, Fantinati P, Bernardini C, Gentilini F, Bacci ML, Forni M. Relationships between innovative and traditional parameters to investigate semen quality in pigs. Anim Reprod Sci 2007;99: 72-81.

[7] De M, Sanford TR, Wood GW. Expression of interleukin 1, interleukin 6 and tumour necrosis factor alpha in mouse uterus during the peri-implantation period of pregnancy. J Reprod Fertil 1993;97: 83-89.

[8] von Wolff M, Classen-Linke I, Heid D, Krusche CA, Beier-Hellwig K, Karl C, Beier HM. Tumour necrosis factor-alpha (TNF-alpha) in human endometrium and uterine secretion: an evaluation by immunohistochemistry, ELISA and semiquantitative RT-PCR. Mol Hum Reprod 1999;5: 146-152.

[9] Schuberth HJ, Taylor U, Zerbe H, Waberski D, Hunter R, Rath D. Immunological responses to semen in the female genital tract. Theriogenology 2008;70: 1174-1181.

[10] Taylor U, Zerbe H, Seyfert HM, Rath D, Baulain U, Langner KF, Schuberth HJ. Porcine spermatozoa inhibit post-breeding cytokine induction in uterine epithelial cells in vivo. Anim Reprod Sci 2009;115: 279-289.

[11] Koçak I, Yenisey C, Dündar M, Okyay P, Serter M. Relationship between seminal plasma interleukin-6 and tumor necrosis factor alpha levels with semen parameters in fertile and infertile men. Urol Res 2002;30: 263-267.

[12] Martínez P, Proverbio F, Camejo MI. Sperm lipid peroxidation and pro-inflammatory cytokines. Asian J Androl 2007;9: 102-107.

[13] Buch JP, Kolon TF, Maulik N, Kreutzer DL, Das DK. Cytokines stimulate lipid membrane peroxidation of human sperm. Fertil Steril 1994;62: 186-188.

[14] Eisermann J, Register KB, Strickler RC, Collins JL. The effect of tumor necrosis factor on human sperm motility in vitro. J Androl 1989;10: 270-274.

[15] Lampiao F, du Plessis SS. TNF-alpha and IL-6 affect human sperm function by elevating nitric oxide production. Reprod Biomed Online 2008;17: 628-631.

[16] Faber BM, Chegini N, Mahony MC, Coddington CC. Macrophage secretory products and sperm zona pellucida binding. Obstet Gynecol 2001;98: 668-673.

[17] De SK, Chen HL, Pace JL, Hunt JS, Terranova PF, Enders GC. Expression of tumor necrosis factor-alpha in mouse spermatogenic cells. Endocrinology 1993;133: 389-396.

[18] Payan-Carreira R, Pires M, Ström Holst B, Rodriguez-Martinez H. Tumour Necrosis Factor in the Canine Endometrium: An Immunohistochemical Study. Reprod Domest Anim 2011;46:410-8.

[19] Kirchhoff C. The dog as a model to study human epididymal function at a molecular level. Mol Hum Reprod. 2002;8:695-701.

[20] Russell LD, Ettlim RA, SinhaHikin AP, ED C. Staging for the dog, Histological and histopathological evaluation of the testis. Clearwater, Florida: Cache River Press, 1990;162-193.

[21] Haider S, Knofler M. Human tumour necrosis factor: physiological and pathological roles in placenta and endometrium. Placenta 2009;30: 111-123.

[22] Suominen JS, Wang Y, Kaipia A, Toppari J. Tumor necrosis factor-alpha (TNF-alpha) promotes cell survival during spermatogenesis, and this effect can be blocked by infliximab, a TNF-alpha antagonist. Eur J Endocrinol 2004;151: 629-640.

[23] Lysiak JJ. The role of tumor necrosis factor-alpha and interleukin-1 in the mammalian testis and their involvement in testicular torsion and autoimmune orchitis. Reprod Biol Endocrinol 2004;2: 9.

[24] Pentikäinen V, Erkkilä K, Suomalainen L, Otala M, Pentikäinen MO, Parvinen M, Dunkel L. TNFalpha down-regulates the Fas ligand and inhibits germ cell apoptosis in the human testis. J Clin Endocrinol Metab 2001;86: 4480-4488.

[25] Siu MK, Cheng CY. Dynamic cross-talk between cells and the extracellular matrix in the testis. Bioessays 2004;26: 978-992.

[26] Sigillo F, Guillou F, Fontaine I, Benahmed M, Le Magueresse-Battistoni B. In vitro regulation of rat Sertoli cell transferrin expression by tumor necrosis factor alpha and retinoic acid. Mol Cell Endocrinol 1999;148: 163-170.

[27] Sylvester SR, Griswold MD. The testicular iron shuttle: a "nurse" function of the Sertoli cells. J Androl 1994;15: 381-385.

[28] Boussouar F, Grataroli R, Ji J, Benahmed M. Tumor necrosis factor-alpha stimulates lactate dehydrogenase A expression in porcine cultured sertoli cells: mechanisms of action. Endocrinology 1999;140: 3054-3062.

[29] Blanco-Rodríguez J. Deoxyribonucleic acid replication and germ cell apoptosis during spermatogenesis in the rabbit. J Androl 2002;23: 182-187.

[30] Blanco-Rodríguez J. DNA replication and germ cell apoptosis during spermatogenesis in the cat. J Androl 2002;23: 484-490.

[31] Cheng CY, Mruk DD. A local autocrine axis in the testes that regulates spermatogenesis. Nat Rev Endocrinol 2010;6: 380-395.

[32] Li MW, Mruk DD, Lee WM, Cheng CY. Cytokines and junction restructuring events during spermatogenesis in the testis: an emerging concept of regulation. Cytokine Growth Factor Rev 2009;20: 329-338.

[33] Lui WY, Lee WM. Molecular mechanisms by which hormones and cytokines regulate cell junction dynamics in the testis. J Mol Endocrinol 2009;43: 43-51.

[34] Qu N, Terayama H, Naito M, Ogawa Y, Hirai S, Kitaoka M, Yi SQ, Itoh M. Caput epididymitis but not orchitis was induced by vasectomy in a murine model of experimental autoimmune orchitis. Reproduction 2008;135: 859-866.

[35] Tanaka K, Fujisawa M, Arakawa S, Kamidono S. Local expression of cytokine messenger RNA in rat model of Escherichia coli epididymitis. J Urol 1995;154: 2179-2184.

[36] Zhao YT, Guo JH, Wu ZL, Xiong Y, Zhou WL. Innate immune responses of epididymal epithelial cells to Staphylococcus aureus infection. Immunol Lett. 2008;119: 84-90

[37] Pang W, Earley B, Sweeney T, Gath V, Crowe MA. Temporal patterns of inflammatory gene expression in local tissues after banding or burdizzo castration in cattle. BMC Vet Res. 2009;5: 36

[38] Robertson SA. Seminal fluid signaling in the female reproductive tract: lessons from rodents and pigs. J Anim Sci 2007;85: E36-44.

[39] Estrada LS, Champion HC, Wang R, Rajasekaran M, Hellstrom WJ, Aggarwal B, Sikka SC. Effect of tumour necrosis factor-alpha (TNF-alpha) and interferon-gamma (IFN-gamma) on human sperm motility, viability and motion parameters. Int J Androl 1997;20: 237-242.

[40] Papadimas J, Goulis DG, Sotiriades A, Daniilidis M, Fleva A, Bontis JN, Tourkantonis A. Interleukin-1 beta and tumor necrosis factor-alpha in normal/infertile men. Arch Androl 2002;48: 107-113.

[41] Rajasekaran M, Hellstrom WJ, Naz RK, Sikka SC. Oxidative stress and interleukins in seminal plasma during leukocytospermia. Fertil Steril 1995;64: 166-171.

Captions:

Table captions

Table 1 – TNF immunoscoring for the germ cell population according to the stage of the canine spermatogenic cycle (1 weak; 2 moderate; 3 strong).

Table 2 – TNF immunoscoring for the epithelium of the different segments of the canine epididymis (1 weak; 2 moderate; 3 strong).

Figure captions:

Figure 1 – **A** – For this study, the epididymides were isolated from the testes and longitudinally cut; the areas used are depicted in this scheme. **B –** TNF immunoreaction in the canine corpus luteum, used as a positive control in this study, for differentiation of the intensity scores (1-weak; 2-moderate;-3 strong) (Bar = 100 μm).

Figure 2 – TNF immunoreaction in the canine testis. In all the images, Sertoli cells (SC) as well as the spermatogonia (SPG) and spermatocytes (SPC) were negative to TNF. (Counterstaining with Gill haematoxylin; Bar = 20 μm) **A** – Within the seminiferous tubules, late round spermatids (rSPD) showed a weak intensity of immunolabelling. **B** – Positive immunostaining was found in early elongating spermatids (eSPD). **C** – Elongated spermatids (egSPD) showed a moderate intensity of immunolabelling for TNF. **D** – A moderate intensity of immunostaining was found in terminal step 12 spermatids (egSPD), at spermiation, whilst spots of strong immunoreaction were observed in a location compatible with residual bodies.

Figure 3 – TNF immunoreaction in the canine epididymis and ejaculated spermatozoa. (Counterstaining with Gill haematoxylin; Bar = 20 μm). BC- Basal cells; PC- Principal cells; AC- Apical cells. **A** – Caput epididymis: the epithelial cells showed weak immunostaining with predominance of a membrane pattern, while the spermatozoa in the

lumen showed a moderate immunolabelling. Sporadically, macrophages (Mø) were observed in the peritubular stroma. **B** – Corpus 1: the epithelium maintains a weak intensity of immunostaining; both membrane and cytoplasmic patterns were present, the later being more notorious in supranuclear position. **C** – Corpus 2: The epithelium showed a moderate intensity of immunoreaction for TNF, which is also found in cell blebbings, while sperm cells presented a strong immunostaining limited to the mid-piece. **D** – Cauda**:** the epithelial cells showed moderate intensity of immunolabelling whereas the sperm cells showed a mid-piece strong immunoreaction against TNF. **E** – Freshly ejaculated spermatozoa had a strong intensity of immunolabelling, which was limited to the sperm mid-piece. **F** – A digital magnification of 2.5x details the subcellular location of the TNF immunoreaction in ejaculated spermatozoa.

Tables

Table 1 – TNF immunoscoring for the germ cell population according to the stage of the canine spermatogenic cycle (1- weak; 2- moderate; 3- strong).

Stage	SPG	SPC	SPD			RB
			round	elongating	elongated	
I	0^{a}	0^{a}	0^{a}	2^{c}	na	na
II	0^{a}	0^{a}	0^{a}	na	2^{c}	na
III	0^{a}	0^{a}	0^{a}	na	2^{c}	na
IV	0^{a}	0^{a}	0^{a}	na	2^{c}	na
V	0^{a}	0^{a}	0^{a}	na	2^{*c}	3^{d}
V.b	0^{a}	0^{a}	1^{b}	na	na	3^{d}
VI	na	0^{a}	na	1^{b}	na	na
VII	na	0^{a}	na	1^{b}	na	na
VIII	na	0^{a}	na	na	2^{c}	na

SPG: Spermatogonia; SPC: spermatocyte; SPD: Spermatid; * Step 12 (terminal) SPD; na: non-appliable; RB: residual bodies. Common superscripts both within row and within column correspond to subsets of the intensity score categories that do not differ significantly at the 0.05 level.

Table 2 – TNF immunoscoring for the epithelium of the different segments of the canine epididymis and for the epididymal spermatozoa (1- weak; 2- moderate; 3- strong).

Location	Epididymal epithelium		Sperm cells
	Intensity	Predominant pattern	Intensity
Caput	1	Membrane	2
Corpus 1	1	Cytoplasmic and membrane	2
Corpus 2	2	Cytoplasmic	3
Cauda	2	Cytoplasmic	3

Figure 1

Click here to download high resolution image

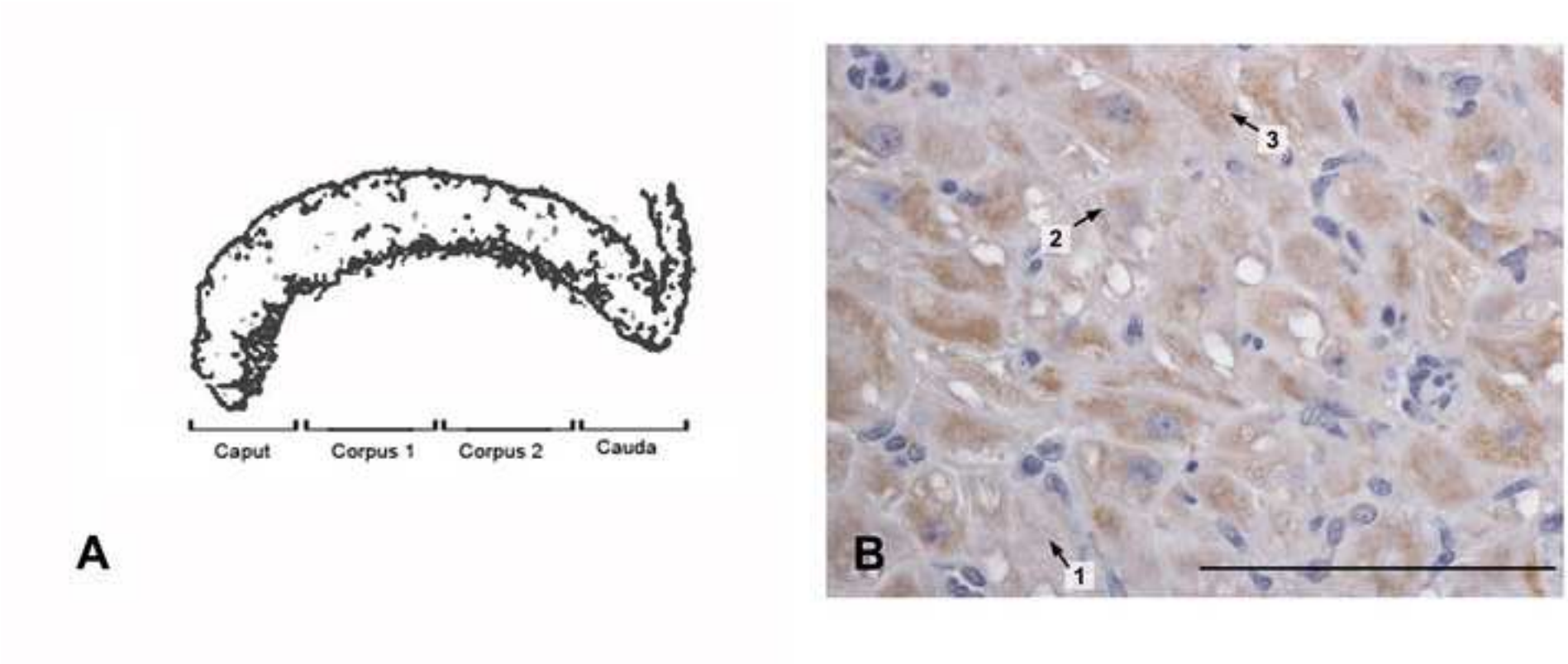

Figure 2
Click here to download high resolution image

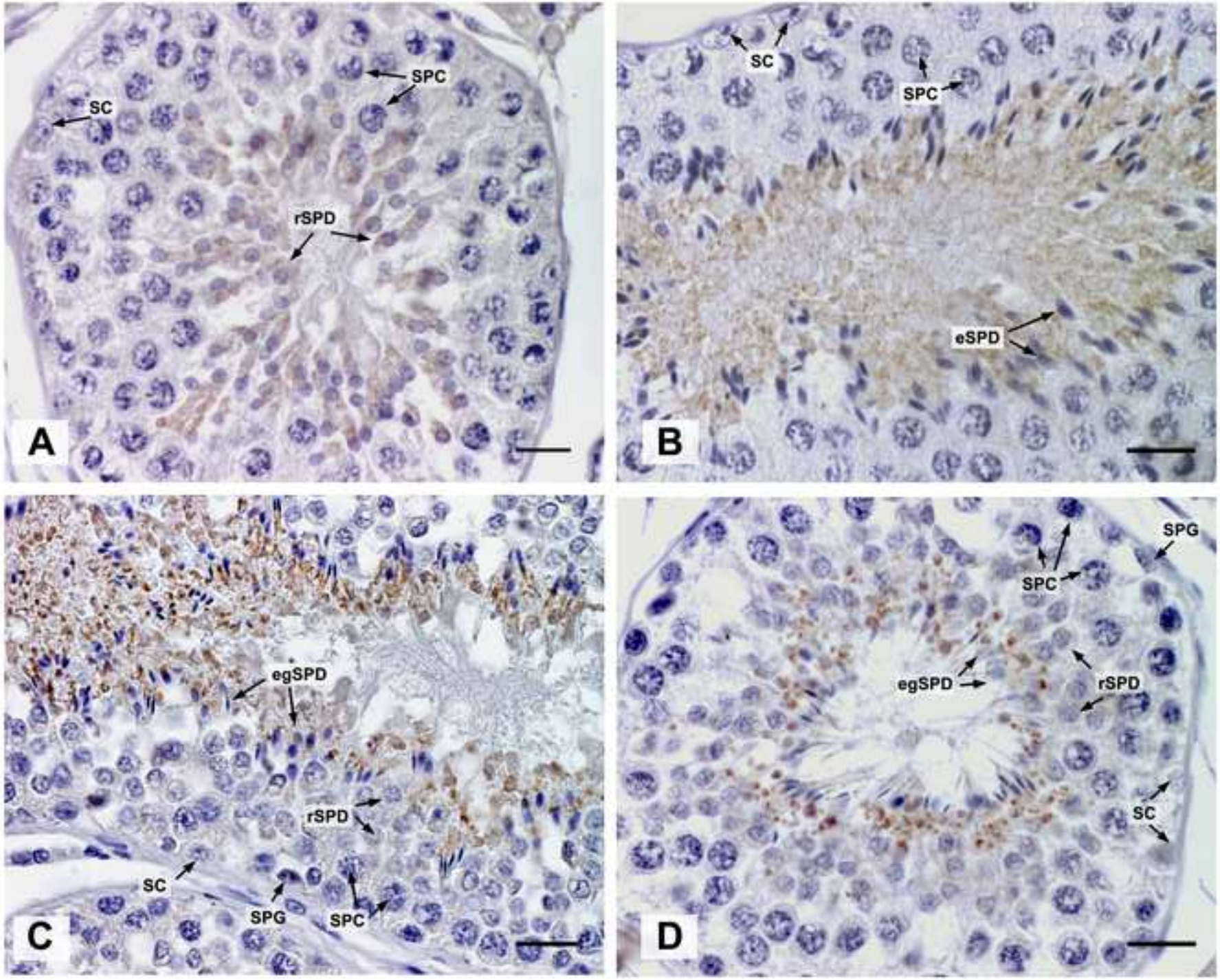
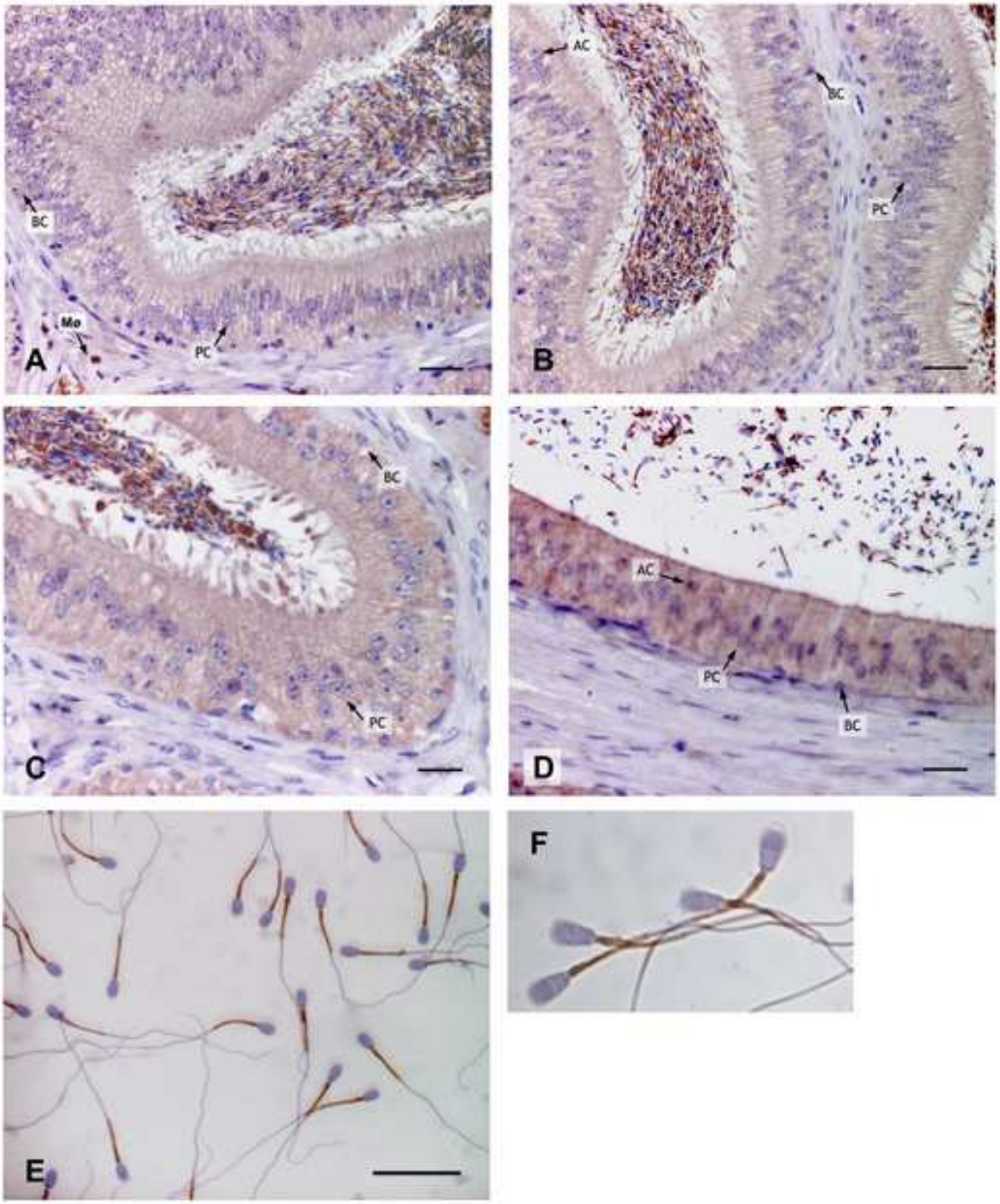
Figure 3
Click here to download high resolution image