





# Preoperative and intraoperative assessment of myometrial invasion in endometrial cancer—A Swedish Gynecologic Cancer Group (SweGCG) study

Björg Jónsdóttir<sup>1</sup>  | Janusz Marcickiewicz<sup>2</sup> | Christer Borgfeldt<sup>3</sup> | Maria Bjurberg<sup>4</sup> | Pernilla Dahm-Kähler<sup>5</sup>  | Angelique Flöter-Rådestad<sup>6</sup> | Kristina Hellman<sup>7</sup> | Erik Holmberg<sup>8</sup> | Preben Kjølhede<sup>9</sup>  | Per Rosenberg<sup>10</sup> | Bengt Tholander<sup>11</sup> | Elisabeth Åvall-Lundqvist<sup>10</sup> | Karin Stålberg<sup>1</sup>  | Thomas Högberg<sup>12</sup>

<sup>1</sup>Department of Women's and Children's Health, Uppsala University, Uppsala, Sweden

<sup>2</sup>Department of Obstetrics and Gynecology, Varbergs Hospital, Region Halland, Sweden

<sup>3</sup>Department of Obstetrics and Gynecology, Skåne University Hospital, and Department of Clinical Sciences, Lund University, Lund, Sweden

<sup>4</sup>Department of Hematology, Oncology, and Radiation Physics, Skåne University Hospital, Lund University, Lund, Sweden

<sup>5</sup>Department of Obstetrics and Gynecology, Sahlgrenska University Hospital, Sahlgrenska Academy at University of Gothenburg, Sweden

<sup>6</sup>Department of Women's and Children's Health, Division of Obstetrics and Gynecology, Karolinska Institutet, Stockholm, Sweden

<sup>7</sup>Department of Gynecologic Cancer, Theme Cancer, Karolinska University Hospital, Stockholm, Sweden

<sup>8</sup>Regional Cancer Center Western Sweden, Gothenburg, Sweden

<sup>9</sup>Department of Obstetrics and Gynecology and Department of Biomedical and Clinical Sciences, Linköping University, Linköping, Sweden

<sup>10</sup>Department of Oncology and Department of Biomedical and Clinical Sciences, Linköping University, Linköping, Sweden

## Abstract

**Introduction:** Deep myometrial invasion ( $\geq 50\%$ ) is a prognostic factor for lymph node metastases and decreased survival in endometrial cancer. There is no consensus regarding which pre/intraoperative diagnostic method should be preferred. Our aim was to explore the pattern of diagnostic methods for myometrial invasion assessment in Sweden and to evaluate differences among magnetic resonance imaging (MRI), transvaginal sonography, frozen section, and gross examination in clinical practice.

**Material and methods:** This is a nationwide historical cohort study; women with endometrial cancer with data on assessment of myometrial invasion and FIGO stage I-III registered in the Swedish Quality Registry for Gynecologic Cancer (SQRGC) between 2017 and 2019 were eligible. Data on age, histology, FIGO stage, method, and results of myometrial invasion assessment, pathology results, and hospital level were collected from the SQRGC. The final assessment by the pathologist was considered the reference standard.

**Results:** In the study population of 1401 women, 32% ( $n = 448$ ) had myometrial invasion of 50% or more. The methods reported for myometrial invasion assessment were transvaginal sonography in 59%, MRI in 28%, gross examination in 8% and frozen section in 5% of cases. Only minor differences were found for age and FIGO stage when comparing methods applied for myometrial invasion assessment. The sensitivity, specificity, and accuracy to find myometrial invasion of 50% or more with transvaginal sonography were 65.6%, 80.3%, and 75.8%, for MRI they were 76.9%, 71.9%, and 73.8%, for gross examination they were 71.9%, 93.6%, and 87.3%, and for frozen section they were 90.0%, 92.7%, and 92.0%, respectively.

**Abbreviations:** EC, endometrial cancer; FIGO, International Federation of Gynecology and Obstetrics; MI, myometrial invasion; MRI, magnetic resonance imaging; SQRGC, Swedish Quality Registry for Gynecologic Cancer; TVS, transvaginal sonography.

This is an open access article under the terms of the Creative Commons Attribution-NonCommercial License, which permits use, distribution and reproduction in any medium, provided the original work is properly cited and is not used for commercial purposes.

© 2021 The Authors. Acta Obstetrica et Gynecologica Scandinavica published by John Wiley & Sons Ltd on behalf of Nordic Federation of Societies of Obstetrics and Gynecology (NFOG)

<sup>11</sup>Department of Oncology, Uppsala University Hospital, Uppsala, Sweden

<sup>12</sup>Department of Medical Oncology, Institute of Clinical Sciences, Lund University, Lund, Sweden

#### Correspondence

Björg Jónsdóttir, Department of Women's and Children's Health, Uppsala University, 75185 Uppsala, Sweden.

Email: bjorg.jonsdottir@kbh.uu.se

#### Funding information

The study was supported by funding from The Swedish Cancer Society.

**Conclusions:** In Sweden, the assessment of deep myometrial invasion is most often performed with transvaginal sonography, but the sensitivity is lower than for the other diagnostic methods. In clinical practice, the accuracy is moderate for transvaginal sonography and MRI.

#### KEYWORDS

deep myometrial invasion, endometrial cancer, frozen section, gross examination, MRI, transvaginal ultrasound

## 1 | INTRODUCTION

Endometrial cancer (EC) is the most common gynecological malignancy in the Nordic countries with about 1400 cases diagnosed every year in Sweden. Most women are diagnosed at an early stage of the disease, resulting in a 5-year overall survival of 84%.<sup>1</sup> The treatment approach and prognosis differ because of stage, histopathological features, and patient characteristics.

The standard treatment for early-stage disease is hysterectomy and bilateral salpingo-oophorectomy with or without lymphadenectomy.<sup>2</sup> Surgical stage is an important prognostic factor and information about lymph node metastases is necessary to accurately determine the stage and decide on postoperative therapy.<sup>3</sup> The prognosis is worse for women with presence of deep ( $\geq 50\%$ ) myometrial invasion (MI), lymphovascular invasion, cervical stromal invasion, FIGO (the International Federation of Gynecology and Obstetrics) grade 3 (poorly differentiated) tumor or non-endometrioid histology. These women also have a higher risk for lymph node metastases.<sup>3-6</sup> For women with endometrioid grade 1 or grade 2 tumors where deep MI is absent the probability of metastases in the pelvic lymph nodes is low and lymphadenectomy is considered unnecessary, avoiding complications such as lymphedema/lymph cyst formation.<sup>7,8</sup> Preoperative triaging is therefore important to select high-risk women for lymphadenectomy and avoid overtreatment of others. However, for women with grade 3 endometrioid histology or non-endometrioid tumors, lymphadenectomy is always recommended and MI assessment is not mandatory.

Both transvaginal sonography (TVS) and magnetic resonance imaging (MRI) can be used for the evaluation of MI, and in experienced hands, TVS is comparable to MRI.<sup>9,10</sup> However, not all hospitals/centers have access to ultrasound experts, and in clinical practice general gynecologists also perform preoperative ultrasound assessments.

Assessment of MI intraoperatively is another option. Many studies have concluded that frozen section is useful because of its high accuracy in diagnosing both histological grade and deep MI.<sup>11,12</sup> Gross examination of the hysterectomy specimen during operation is another option, and is probably the most easily applied method for the evaluation of MI. Studies on gross examination have found comparable results with the final histological evaluation.<sup>13</sup> In comparison,

### Key message

The assessment of deep myometrial invasion in endometrial cancer is most commonly performed with transvaginal sonography (TVS) in Sweden. However, the accuracy for predicting deep myometrial invasion is moderate for TVS and MRI and the sensitivity for TVS is lower than for MRI.

intraoperative examination of frozen sections has a better diagnostic performance than intraoperative gross evaluation.<sup>14</sup> However, both of these methods are challenging for surgery planning as it is not known before surgery if lymphadenectomy is to be performed or not.

In 2017, assessment of MI was included in the Swedish National Guidelines for Endometrial Cancer.<sup>15</sup> It was recommended as part of the preoperative risk evaluation to decide whether to perform lymphadenectomy or not. There is no national consensus regarding which method should be used for MI assessment, and the hospitals may have different approaches.

The aim of this study was to explore the pattern of different diagnostic methods for assessing MI in EC using data from the Swedish Quality Registry for Gynecologic Cancer (SQRGC) and to evaluate the sensitivity, specificity, positive and negative predictive values, and accuracy of the methods. This is the first study to evaluate imaging of MI in an unselected national cohort.

## 2 | MATERIAL AND METHODS

This is a population-based historical cohort study with nationwide data from the SQRGC.

### 2.1 | The Swedish Quality Registry for Gynecologic Cancer

All residents of Sweden are allocated a personal identification number, which facilitates the operation of official registries and research.

Reporting to the Swedish Cancer Registry, which was founded in 1958, is mandatory for both clinicians and pathologists. The registry has over 96% coverage of all malignant tumors compared with the Swedish Hospital Discharge register, and in 99% of cases the morphology is verified.<sup>16</sup> However, clinical data including treatment and follow up are not registered. Hence, the SQRGC was established in 2008. Reporting to the SQRGC is performed prospectively by all hospitals and clinics in Sweden. The registration is web-based and includes information on patient and tumor characteristics, details of treatments and outcome, as well as clinical follow-up data for 5 years. The SQRGC continuously receives data on date of death from the Population Registry.<sup>17</sup> The registration for uterine malignancies in the SQRGC started in 2010. Details of the SQRGC have been described previously.<sup>18</sup>

Considering the number of patients reported with uterine malignancies, the SQRGC shows high coverage (96%) compared with the Swedish Cancer Registry.<sup>18</sup> The validity of the recorded data in the SQRGC for uterine malignancies has previously been assessed in a study where 268 patients were randomly selected and the agreement between the review of the patient records and the registered data was between 72% and 98% for 12 core variables, with the largest differences for dates.<sup>18</sup>

Data on the preoperative assessment of MI have been included in the SQRGC since 2017. It was only possible to register one method for this assessment. Deep MI was classified as  $\geq 50\%$  tumor infiltration of the thickness of the myometrium. The result of the uterine histopathology assessment of the hysterectomy specimen was recorded by the clinician.

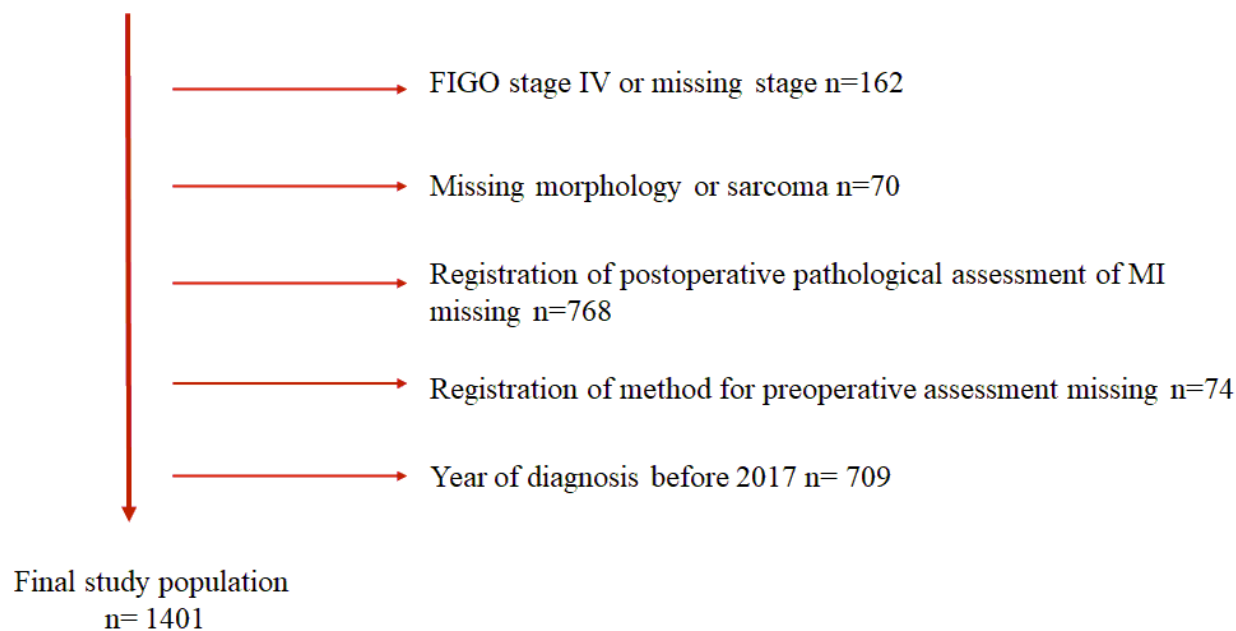
## 2.2 | Study population

Women with EC in the SQRGC with a registration date between January 2017 and December 2019 and with data on preoperative or intraoperative MI assessments were eligible for the study. Exclusion criteria were FIGO Stage IV disease, sarcoma, missing information on morphology, and missing information on the postoperative pathological assessment or the preoperative method for MI assessment (Figure 1). The following data were collected from the SQRGC: age, histology, FIGO stage (determined after histopathological examination), method and result of preoperative or intraoperative MI assessment, pathology results, and location of assessment (university hospital/non-university hospital).

## 2.3 | The Swedish National Guidelines and setting

In 2017, assessment of MI was included as a mandatory part of the workup in the Swedish National Guidelines for Endometrial Cancer. It is recommended as a part of the risk evaluation to decide whether to perform lymphadenectomy. There is no national consensus regarding which method should be used. The guidelines recommend the use of contrast-enhanced MRI with or without diffusion-weighted imaging. It is further recommended that TVS for assessment of MI is performed by a gynecologist with "second-opinion" competence, that is, an education approved by the Swedish Society of Obstetrics and Gynecology.<sup>15</sup>

### All women with uterine malignancies in the register (SQRGC) with a pre/intraoperative MI assessment 2851



**FIGURE 1** Flow chart showing the selection of the final study population. Several exclusion criteria can be fulfilled in one patient. Abbreviations: MI, myometrial invasion; SQRGC, Swedish Quality Registry for Gynecologic Cancer.

During the study period most EC surgeries requiring lymphadenectomies were performed in specialized referral centers in Sweden. Other surgeries were performed in all gynecological centers in Sweden and the histopathological evaluation took place at the operating hospital.

## 2.4 | Statistical analyses

The result of the pathological assessment of paraffin-embedded uterine samples was considered the reference standard for the statistical analyses. The results of TVS, MRI, gross examination, and frozen section regarding MI were compared with the reference standard and the sensitivity, specificity, positive predictive value, negative predictive value, area under the receiver operating characteristics curve and accuracy were determined for all tumors and for low-risk (endometrioid grade 1–2) tumors separately. The prevalence of deep MI was estimated in the whole cohort ( $n = 9851$ ) of FIGO Stage I–III endometrial carcinomas. Of those, 3262 (33.1%) had deep MI, and the corresponding figure for endometrioid grade 1–2 was 29.6%. Those prevalences were used in estimating the positive and negative predicted values, based on Bayes' theorem. The STATA Statistical Software release 16 (StataCorp) was used.

## 2.5 | Ethical approval

This project is covered by the general ethical approval of the endometrial registry of the SQRGC (Regional Ethics Committee in Gothenburg D.nr.814-15, November 20, 2015).

## 3 | RESULTS

The final study population included 1401 women (Figure 1).

Table 1 illustrates the final study cohort of which 91% had endometrioid adenocarcinoma and 83% were in FIGO Stage I. The method reported for the evaluation of MI was TVS in 59% of cases, MRI in 28%, gross examination in 8%, and frozen section in 5%. The prevalence of deep MI was 32% in the study population, based on the final histopathology (Table 1).

Examination with TVS was more common in women with endometrioid tumors (771/1270, 61%) than in women with non-endometrioid tumors (22/131, 46%) ( $p < 0.001$ ) (Table 2). Gross examination was reported in 17% (22/131) of the non-endometrioid cases compared with 6% (80/1270) of the endometrioid cases ( $p < 0.001$ ). Non-university hospitals more often reported use of frozen sections (57/477, 12%) than university hospitals (18/904, 2%) ( $p < 0.001$ ). Only minor differences were found for age or FIGO stage when comparing the methods for MI assessment.

In Table 3 the results of the different methods for assessing MI are shown. In the total study population, deep MI was wrongly

**TABLE 1** Clinical and pathological characteristics of the study population

	Study population ( $n = 1401$ ) $n$
Age (years), median (interquartile range)	70 (62–77)
Year of diagnosis	
2017	654 (46.7%)
2018	486 (34.7%)
2019	261 (18.6%)
Endometrioid adenocarcinoma	1270 (90.7%)
Endometrioid grade 1	717 (56.5%)
Endometrioid grade 2	398 (31.3%)
Endometrioid grade 3	113 (8.9%)
Endometrioid not graded	42 (3.3%)
Non-endometrioid carcinoma	131 (9.4%)
Serous adenocarcinoma	69 (4.9%)
Clear-cell carcinoma	35 (2.5%)
Carcinosarcoma	27 (1.9%)
FIGO Stage <sup>a</sup>	
IA	870 (62.1%)
IB	296 (21.1%)
II	95 (6.8%)
III	140 (10.0%)
Myometrial invasion <sup>a</sup>	
<50%	953 (68.0%)
≥50%	448 (32.0%)
Method for myometrial invasion assessment	
TVS	831 (59.3%)
MRI	385 (27.5%)
Gross examination	110 (7.9%)
Frozen section	75 (5.4%)
Type of hospital	
University hospital	904 (64.5%)
Non-university hospital	477 (34.1%)
Unknown	20 (1.4%)

Abbreviations: MI, myometrial invasion; MRI, magnetic resonance imaging; TVS, transvaginal sonography.

<sup>a</sup>Determined by final histopathology.

assessed in 322 patients (22.9%). The sensitivity was highest for frozen section (90.0%) and lowest for TVS (65.6%). The intraoperative methods (gross examination and frozen section) had higher specificity and accuracy than the preoperative methods (MRI and TVS). Frozen section was the method closest to the final pathology report, with 90.0% sensitivity, 92.7% specificity and 92.0% accuracy. For transvaginal ultrasound the sensitivity and specificity for detecting deep MI were 65.6% and 80.3% and for MRI they were 76.9% and 71.9%, respectively, whereas for gross examination it was 71.9% and 93.6%. Since the results of MI assessment are more important for low-risk tumors (endometrioid grade 1–2)

TABLE 2 Patients' characteristics by method for assessing myometrial invasion (final histopathology as reference)

	TVS n = 831 59.3%	MRI n = 385 27.5%	GE n = 110 7.9%	FS n = 75 5.4%	Total n = 1,401 100%
Age (years), median (interquartile range)	71 (63–77)	69 (60–76)	70 (62–75)	69 (59–76)	70 (62–77)
Morphology					
Endometrioid	771 (92.8%)	344 (89.4%)	88 (80.0%)	57 (89.3%)	1270 (90.2%)
Endometrioid grade 1	449 (58.2%)	179 (52.0%)	49 (55.7%)	40 (59.7%)	717 (56.5%)
Endometrioid grade 2	234 (30.4%)	123 (35.8%)	21 (23.9%)	20 (29.9%)	398 (31.3%)
Endometrioid grade 3	65 (8.4%)	30 (8.7%)	12 (13.6%)	6 (9.0%)	113 (8.9%)
Not graded	23 (3.0%)	12 (3.5%)	6 (6.8%)	1 (1.5%)	42 (3.3%)
Non-endometrioid	60 (7.2%)	41 (10.7%)	22 (20.0%)	8 (10.7%)	131 (9.4%)
FIGO Stage <sup>a</sup>					
IA	526 (63.3%)	221 (57.4%)	73 (66.4%)	50 (66.7%)	870 (62.1%)
IB	174 (20.9%)	86 (22.3%)	19 (17.3%)	17 (22.7%)	296 (21.1%)
II	56 (6.7%)	30 (7.8%)	4 (3.6%)	5 (6.7%)	95 (6.8%)
III	75 (9.0%)	48 (12.5%)	14 (12.7%)	3 (4.0%)	140 (10.0%)
Type of hospital					
University hospital	580 (69.8%)	259 (67.3%)	47 (42.7%)	18 (24.0%)	904 (64.5%)
Non-university hospital	244 (29.4%)	115 (29.9%)	61 (55.5%)	57 (76.0%)	477 (34.1%)
Unknown	7 (0.8%)	11 (2.9%)	2 (1.8%)	0 (0.0%)	20 (2.1%)

Abbreviations: FS, frozen section; GE, gross examination; MRI, magnetic resonance imaging; TVS, transvaginal sonography.

<sup>a</sup>Determined by final histopathology.

TABLE 3 Sensitivity, specificity, positive predictive value, negative predictive value, ROC-AUC, and accuracy of the methods used for assessing deep myometrial invasion compared with the final paraffin-embedded pathology evaluation

Method (n)	Sensitivity % (95% CI)	Specificity % (95% CI)	PPV % (95% CI) <sup>a</sup>	NPV % (95% CI) <sup>a</sup>	ROC-AUC (95% CI)	Accuracy % (95% CI)
TVS (831)	65.6 (59.4–71.4)	80.3 (76.8–83.4)	62.2 (57.7–66.5)	82.5 (79.8–84.9)	0.73 (0.70–0.76)	75.8 (72.8–78.1)
Low risk (683)	62.3 (54.8–69.3)	81.2 (77.5–84.5)	83.9 (62.3–94.3)	87.8 (77.6–93.7)	0.82 (0.69–0.94)	76.1 (72.8–79.2)
MRI (385)	76.9 (69.1–83.6)	71.9 (65.8–77.5)	57.5 (52.1–62.8)	86.3 (82.2–89.6)	0.74 (0.70–0.79)	73.8 (69.1–78.1)
Low risk (302)	74.5 (64.7–82.8)	74.0 (67.4–79.9)	58.2 (58.2–52.9)	83.7 (80.9–86.19)	0.72 (0.68–0.71)	74.1 (68.8–79.0)
GE (110)	71.9 (53.3–86.3)	93.6 (85.7–97.9)	84.7 (69.8–93.0)	87.1 (79.4–92.1)	0.83 (0.74–0.91)	87.3 (79.6–92.9)
Low risk (70)	68.8 (41.3–89.0)	94.4 (84.6–98.8)	83.9 (62.3–94.3)	87.8 (77.6–93.7)	0.82 (0.69–0.94)	88.6 (78.7–94.9)
FS (75)	90.0 (68.3–98.8)	92.7 (82.4–98.0)	86.0 (70.2–94.1)	94.9 (83.4–98.6)	0.91 (0.84–0.99)	92.0 (83.4–97.0)
Low risk (60)	92.3 (64.0–99.8)	93.6 (82.5–98.7)	85.9 (66.8–94.8)	96.7 (81.5–99.5)	0.93 (0.85–1)	93.3 (83.8–98.2)

Abbreviations: FS, frozen section; GE, gross examination; MRI, magnetic resonance imaging; NPV, negative predictive value; PPV, positive predictive value; ROC-AUC, receiver operating characteristics area under the curve; TVS, transvaginal ultrasound.

Low risk: Endometrioid histology grade 1 and 2.

<sup>a</sup>Values and confidence intervals are based on likelihood ratios and a prevalence of 33.1% for deep myometrial invasion in the whole cohort of endometrial carcinomas FIGO Stages I–III in the register.

and decisive for lymphadenectomy, we performed separate analyses for this subgroup and the sensitivity was slightly lower for TVS (62.3%) and MRI (74.5%) and the specificity was slightly better in all methods.

In Table 4 the sensitivity and specificity were calculated for TVS and MRI divided by year of diagnosis and no obvious variations were noted.

## 4 | DISCUSSION

In this nationwide registry-based cohort study of the clinical assessment of deep MI in EC, TVS was the most common method reported, followed by MRI, intraoperative gross examination, and frozen section.

**TABLE 4** The sensitivity, specificity, and ROC-AUC of transvaginal ultrasound and magnetic resonance imaging compared with the final histopathology by year of diagnosis

Year of diagnosis	TVS			MRI				
	n	Sensitivity % (95% CI)	Specificity % (95% CI)	ROC-AUC (95% CI)	n	Sensitivity % (95% CI)	Specificity % (95% CI)	ROC-AUC (95% CI)
2017	415	68.0 (59.1–76.1)	81.0 (76.0–85.4)	0.75 (0.70–0.79)	147	77.4 (63.8–87.7)	73.4 (63.3–82.0)	0.75 (0.68–0.83)
2018	290	63.9 (52.6–74.1)	77.3 (71.0–82.8)	0.71 (0.65–0.77)	148	78.0 (65.3–87.7)	71.9 (61.4–80.9)	0.75 (0.68–0.82)
2019	126	62.2 (46.5–76.2)	85.2 (75.6–92.1)	0.74 (0.66–0.82)	90	74.2 (55.4–88.1)	69.5 (56.1–80.8)	0.72 (0.62–0.82)

Abbreviations: MRI, magnetic resonance imaging; ROC-AUC, receiver operating characteristics area under the curve; TVS, transvaginal ultrasound.

The highest sensitivity (90%) to find MI  $\geq$ 50% was found for frozen section whereas the sensitivity was lower for gross examination (72%). For the preoperative methods, the sensitivity of MRI (77%) was found to be higher than that of TVS (66%). Positive predictive values were lower than 63% for both TVS and MRI, perhaps showing that neither of the methods is optimum for diagnosing deep MI.

The most commonly used method for MI assessment in the study was TVS. We found a lower sensitivity for ultrasound assessment than reported in previous studies.<sup>10</sup> In a systematic review, the pooled sensitivity and specificity of TVS were found to be 82% and 81%, respectively, compared with 65% and 81% in the current study.<sup>19</sup> It should be kept in mind when comparing the results with those of other studies, however, that the retrospective design of the current study may result in lower validity. However, the discrepancy between the sensitivity of the MRI assessment compared with ultrasound was greater than expected,<sup>10</sup> although with overlapping confidence intervals. In our opinion, the sensitivity might be more important when estimating MI because with higher sensitivity more patients with deep MI are identified, staged, and treated accordingly. However, with the higher rate of false positives that MRI had in this study, along with the lowest specificity, more patients will be unnecessarily staged with lymphadenectomies, resulting in an unnecessarily high rate of complications. In this study, gross examination and TVS had a high false-negative rate, so were missing patients that truly had deep MI, possibly resulting in second operations for these patients for staging with lymphadenectomies.

In most previous studies on TVS in EC, the examiners have been ultrasound experts and according to the European Society for Medical Oncology-European Society of Gynecological Oncology-European Society for Radiotherapy and Oncology consensus it is recommended that the MI evaluation is performed by an ultrasound expert or using MRI or intraoperative methods.<sup>2</sup> However, not all centers in Sweden have access to an ultrasound expert and sometimes these examinations are performed by less experienced examiners. To our knowledge, there is only one study published that compares the MI assessment of both general gynecologists and ultrasound experts, which included 53 cases, and found no difference in their assessment.<sup>20</sup> This contradicts the possible reason for the lower sensitivity of TVS in this study being less experienced examiners. However,

in another previous study by Green et al, accuracy was correlated to the number of cases the examiner assessed annually.<sup>21</sup> MRI assessment of MI in previous studies was often performed by senior radiologists, but in our study, we do not have information on the examiners.

Previously, objective measurement techniques have been introduced, such as use of the tumor/uterine anteroposterior diameter ratio<sup>22</sup> or measuring the tumor-free margin.<sup>23</sup> However, compared with the subjective assessment of an ultrasound expert these methods have not been found to be more accurate.<sup>24</sup> In the current study it is not known which method was applied during the ultrasound assessment. The objective measures are possibly more suitable for inexperienced sonographers in the assessment of MI and could thereby increase the sensitivity of the method; however, this has to our knowledge not been studied.

Overall, the results for the perioperative methods are comparable with earlier studies. The strength of gross examination lies in its simplicity, low cost, and immediate results. The quality of the method is influenced by the surgeon implementing it and his/her experience. In this study no information on the surgeon's experience was available and the range of sensitivity and specificity could differ between individuals. In spite of this, the accuracy of this method in the study was 87% compared with 87% in a previous prospective Swedish study.<sup>25</sup> The same accuracy (87%) was found in a meta-analysis by Mavromatis et al.<sup>13</sup>

The assessment of MI with frozen section has previously been found to be a reliable method with high accuracy,<sup>12,26</sup> and this is confirmed by the current study, which showed 92% accuracy in clinical practice. However, this method was applied in only 5% of cases.

The intraoperative methods have the disadvantage that their results are not known until during surgery and are dependent on a pathologist being available on-site, which is not possible in all clinics.

Previous studies have suggested a combined approach for assessing deep MI with both preoperative and intraoperative methods to increase the sensitivity, and this could be considered in cases with a difficult assessment before surgery. Akbayr et al found that a combination of TVS and intraoperative gross examination enhances the sensitivity and negative predictive value,<sup>27</sup> and Kisu et al<sup>28</sup> suggest combining MRI and frozen section in selected cases based on the different diagnostic

characteristics of the two methods, where MRI has a high negative predictive value.

This is the first nationwide, population-based study on the assessment of MI in EC. The strength of this study is its size, with 1400 women with EC included from all parts of Sweden. Data are extracted from the validated<sup>16</sup> SQRGC providing information on assessment of MI in clinical practice. The data are recorded prospectively at time of treatment, minimizing the risk of bias.

As in all large register studies, some limitations must be addressed. In the SQRGC, only one method for the assessment of MI could be registered and it is unknown which method was chosen if more than one was applied; it is also not known whether the use of additional methods has influenced the assessment. Additionally, the reason for choosing each method was not known. There were some differences in choice of method by morphology where vaginal ultrasound was applied more often in endometrioid than in non-endometrioid tumors. Furthermore, the experience of the physician responsible for the evaluation of MI was not stated, and nor were the skills of the MRI radiologists. TVS was a much larger group, which made the comparison between groups unbalanced. In addition, assessment of MI was included in the national guidelines in 2017 and a learning curve was to be expected in TVS and possibly also in MRI. However, when divided by years, no major difference was found in the sensitivity in the years after implementation. Accordingly, these results should be interpreted in the context of a clinical real-life scenario and should not be compared with the results from controlled, prospective imaging studies where the examinations have been assessed by experts.

The results of this study could lead to improvements of the implementation of deep MI assessment in Sweden. It is possible that in some centers a renewal of equipment is needed, or additional education on imaging. Further, the number of cases needed per year to obtain higher sensitivity should be addressed in regard to each center.

As the present study demonstrates rather poor positive predictive values of detecting deep MI for both TVS and MRI, the results strengthen the growing implementation of sentinel node biopsy for all ECs instead of relying on these diagnostic methods. Deep MI not only increases the risk of lymph node metastases<sup>5</sup> but it is believed to be an independent prognostic factor<sup>3</sup> and is predictive for recurrence.<sup>4</sup> In addition, the sentinel node procedure is still not in common practice in many parts of the world. In a recent survey study,<sup>29</sup> around 50% of physicians from 69 different countries (the majority from Europe and the USA) had adopted the sentinel node concept, and worldwide the frequency is probably lower and accordingly there is still a need for tools for selecting high-risk patients in centers that do not perform the sentinel node procedure.<sup>29</sup>

## 5 | CONCLUSION

In Sweden the assessment of deep MI in EC is usually performed with TVS. The sensitivity of TVS was lower in clinical practice than that of MRI. This means that more women with high-risk tumors are

falsely classified as low-risk and have possibly not been primarily operated adequately with lymphadenectomy as recommended. This could lead to under-staging and may possibly worsen the prognosis for women who should have received adjuvant treatment. However, it should be kept in mind that some high-risk tumors are correctly diagnosed with a pathology analysis of a preoperative endometrial biopsy without the estimation of MI. Neither TVS nor MRI was optimal for estimating deep MI as both had relatively low positive predictive values and the accuracy for predicting deep MI was moderate for both methods. It is therefore important to examine which method for the assessment of deep MI is most applicable in each center with regard to the examiners' competence, and to improve reporting and quality controls if the sentinel node concept is not adopted for all patients.

## CONFLICT OF INTERESTS

Elisabeth Åvall-Lundqvist has received honoraria from Roche; and served on advisory boards for Astra Zeneca, Clovis Oncology, Tesaro, and Genmab. The other authors have no conflicts of interest to declare.

## ORCID

Björg Jónsdóttir  <https://orcid.org/0000-0001-8962-4351>

Pernilla Dahm-Kähler  <https://orcid.org/0000-0002-6699-893X>

Preben Kjølhede  <https://orcid.org/0000-0001-5702-4116>

Karin Stålberg  <https://orcid.org/0000-0001-5527-8796>

## REFERENCES

1. NORDCAN AotNCR. Cancer stat fact sheet. <http://www.dep.iarc.fr/NORDCAN/SW/StatsFact.asp?cancer=222&country=752.2020>.
2. Colombo N, Creutzberg C, Amant F, et al. ESMO-ESGO-ESTRO consensus conference on endometrial cancer: diagnosis, treatment and follow-up. *Radiother Oncol*. 2015;117:559-581.
3. Creasman W, Odicino FT, Maisonneuve P, et al. Carcinoma of the corpus uteri, FIGO 26th annual report on the results of treatment in gynecological cancer. *Int J Gynaecol Obstet*. 2006;95(Suppl 1):S105-S143.
4. Sorbe B. Predictive and prognostic factors in definition of risk groups in endometrial carcinoma. *ISRN Obstet Gynecol*. 2012;2012:325790.
5. Stalberg K, Kjølhede P, Bjurberg M, et al. Risk factors for lymph node metastases in women with endometrial cancer: A population-based, nation-wide register study on behalf of the Swedish Gynecological Cancer Group. *Int J Cancer*. 2017;140:2693-2700.
6. Stalberg K, Bjurberg M, Borgfeldt C, et al. Lymphovascular space invasion as a predictive factor for lymph node metastases and survival in endometrioid endometrial cancer – a Swedish Gynecologic Cancer Group (SweGCG) study. *Acta Oncol*. 2019;58:1628-1633.
7. Frost JA, Webster KE, Bryant A, Morrison J. Lymphadenectomy for the management of endometrial cancer. *Cochrane Database Syst Rev*. 2017;10:CD007585.
8. Cragun JM, Havrilesky LJ, Calingaert B, et al. Retrospective analysis of selective lymphadenectomy in apparent early-stage endometrial cancer. *J Clin Oncol*. 2005;23:3668-3675.
9. Antonsen SL, Jensen LN, Loft A, et al. MRI, PET/CT and ultrasound in the preoperative staging of endometrial cancer – a multicenter prospective comparative study. *Gynecol Oncol*. 2013;128:300-308.

10. Savelli L, Ceccarini M, Ludovisi M, et al. Preoperative local staging of endometrial cancer: transvaginal sonography vs. magnetic resonance imaging. *Ultrasound Obstet Gynecol.* 2008;31:560-566.
11. Kobayashi H, Otsuki Y, Kato A, Kobayashi M, Adachi H. Is an intraoperative frozen section useful for judging the necessity of lymphadenectomy in patients with endometrial cancer? *J Clin Gynecol Obstet.* 2019;8:9-16.
12. Kumar S, Medeiros F, Dowdy SC, et al. A prospective assessment of the reliability of frozen section to direct intraoperative decision making in endometrial cancer. *Gynecol Oncol.* 2012;127:525-531.
13. Mavromatis ID, Antonopoulos CN, Matsoukis IL, et al. Validity of intraoperative gross examination of myometrial invasion in patients with endometrial cancer: a meta-analysis. *Acta Obstet Gynecol Scand.* 2012;91:779-793.
14. Alcazar JL, Dominguez-Piriz J, Juez L, Caparros M, Jurado M. Intraoperative gross examination and intraoperative frozen section in patients with endometrial cancer for detecting deep myometrial invasion: a systematic review and meta-analysis. *Int J Gynecol Cancer.* 2016;26:407-415.
15. Cancer SNGfE. Swedish National Guidelines for Endometrial Cancer. <https://kunskapsbanken.cancercentrum.se/diagnoser/livmoderkroppscancer/varprogram/>.
16. Barlow L, Westergren K, Holmberg L, Talback M. The completeness of the Swedish Cancer Register: a sample survey for year 1998. *Acta Oncol.* 2009;48:27-33.
17. Brooke HL, Talback M, Hornblad J, et al. The Swedish cause of death register. *Eur J Epidemiol.* 2017;32:765-773.
18. Rosenberg P, Kjolhede P, Staf C, et al. Data quality in the Swedish Quality Register of Gynecologic Cancer – a Swedish Gynecologic Cancer Group (SweGCG) study. *Acta Oncol.* 2018;57:346-353.
19. Alcazar JL, Orozco R, Martinez-Astorquiza Corral T, et al. Transvaginal ultrasound for preoperative assessment of myometrial invasion in patients with endometrial cancer: a systematic review and meta-analysis. *Ultrasound Obstet Gynecol.* 2015;46:405-413.
20. Eriksson LS, Lindqvist PG, Floter Radestad A, et al. Transvaginal ultrasound assessment of myometrial and cervical stromal invasion in women with endometrial cancer: interobserver reproducibility among ultrasound experts and gynecologists. *Ultrasound Obstet Gynecol.* 2015;45:476-482.
21. Green RW, Valentin L, Alcazar JL, et al. Endometrial cancer off-line staging using two-dimensional transvaginal ultrasound and three-dimensional volume contrast imaging: intermethod agreement, interrater reliability and diagnostic accuracy. *Gynecol Oncol.* 2018;150:438-445.
22. Karlsson BNA, Granberg S, Wikland M. The use of endovaginal ultrasound to diagnose invasion of endometrial carcinoma. *Ultrasound Obstet Gynecol.* 1992;2:35-39.
23. Alcazar JL, Galvan R, Albela S, et al. Assessing myometrial infiltration by endometrial cancer; uterine virtual navigation with three-dimensional US. *Radiology.* 2009;250:776-783.
24. Fruhauf F, Zikan M, Semeradova I, et al. The diagnostic accuracy of ultrasound in assessment of myometrial invasion in endometrial cancer: subjective assessment versus objective techniques. *Biomed Res Int.* 2017;2017:1318203.
25. Marcickiewicz J, Sundfeldt K. Accuracy of intraoperative gross visual assessment of myometrial invasion in endometrial cancer. *Acta Obstet Gynecol Scand.* 2011;90:846-851.
26. Gitas G, Proppe L, Alkatout I, et al. Accuracy of frozen section at early clinical stage of endometrioid endometrial cancer: a retrospective analysis in Germany. *Arch Gynecol Obstet.* 2019;300:169-174.
27. Akbayir O, Corbacioglu A, Numanoglu C, et al. Combined use of preoperative transvaginal ultrasonography and intraoperative gross examination in the assessment of myometrial invasion in endometrial carcinoma. *Eur J Obstet Gynecol Reprod Biol.* 2012;165:284-288.
28. Kisu I, Banno K, Lin LY, et al. Preoperative and intraoperative assessment of myometrial invasion in endometrial cancer: comparison of magnetic resonance imaging and frozen sections. *Acta Obstet Gynecol Scand.* 2013;92:525-535.
29. Casarin J, Multinu F, Abu-Rustum N, et al. Factors influencing the adoption of the sentinel lymph node technique for endometrial cancer staging: an international survey of gynecologic oncologists. *Int J Gynecol Cancer.* 2019;29:60-67.

**How to cite this article:** Jónsdóttir B, Marcickiewicz J, Borgfeldt C, et al. Preoperative and intraoperative assessment of myometrial invasion in endometrial cancer—A Swedish Gynecologic Cancer Group (SweGCG) study. *Acta Obstet Gynecol Scand.* 2021;100:1526–1533. <https://doi.org/10.1111/aogs.14146>